

Patient: John A. Doe



Case No: P11-00647

DOB/Gender: xx/xx/xxxx (74 yrs) - Male

SSN: xxx-xx-xxxx

MRN/ID: xxxxx

4 Science Park, 3<sup>rd</sup> Floor, New Haven, CT 06511  
Phone: 203-787-7888 Fax: 203-901-1289  
www.precipiodx.com

Collected: xx/xx/xx

Received: xx/xx/xx

Reported: xx/xx/xx

Provider: Jane Smith, M.D.

Account: Hematology Oncology Associates

Phone: 800-123-4567 Fax: 800-765-4321

Alert Status: Routine

Report Status: Final

Report Category: **Neoplastic**

Clinical information: Monocytosis. Leukocytosis. Splenomegaly.

Received information: 2 Formalin containers, 9 smears, 1 touch prep, 2 green-top tubes, 1 lavender-top tube



## COMPREHENSIVE DIAGNOSIS

Professional Services Provided By  
Yale SCHOOL OF MEDICINE

### FINAL DIAGNOSIS:

**Chronic myelomonocytic leukemia (CMML) and monoclonal B-cell lymphocytosis (MBL) (see comment)**

### COMMENT:

The findings are consistent with involvement by a MYELOYDYSPLASTIC SYNDROME/MYELOPROLIFERATIVE NEOPLASM. Given the history of an unexplained persistent absolute monocytosis, the morphologic findings are consistent with involvement by CHRONIC MYELOMONOCYTIC LEUKEMIA (CMML). The presence of less than 5% blasts further categorizes this into CMML-o and a white blood cell count less than  $13 \times 10^9/L$  favors the "dysplastic type" according to the 2016 revision to the WHO (Arber DA, Blood 2016). If clinically indicated, molecular analysis for SRSF2, TET2 and ASXL1, which is found in more than 80% of cases, may be performed.

In addition, flow cytometry identified a small kappa monoclonal B cell population which based on the patient's lymphocyte count is consistent with a MONOCLONAL B CELL LYMPHOCYTOSIS (MBL). Correlation with clinical and laboratory findings is advised.

Electronically Signed By: Demetrios Braddock, MD, PhD

### RESULT SUMMARY:

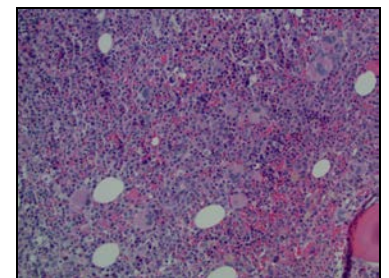
Biopsy: **Myelodysplastic syndrome/myeloproliferative neoplasm (see comment)**

Aspirate: Maturing trilineage hematopoiesis with occasional trilineage dysplasia and a monocytosis

Flow Cytometry: Monoclonal B-cell lymphocytosis (MBL) (see comment)

Karyotyping: Normal male karyotype (see interpretation)

FISH: No Clonal Abnormalities Detected, see interpretation below



Myeloid-rich, Hypercellular Marrow



**BONE MARROW BIOPSY**

**DIAGNOSIS:**

**Bone marrow, core & clot biopsies: Myelodysplastic syndrome/myeloproliferative neoplasm (see comment)**

**COMMENT:**

The findings are consistent with involvement by a MYELOYDYSPLASTIC SYNDROME/MYELOPROLIFERATIVE NEOPLASM. Given the history of an unexplained persistent absolute monocytosis, the morphologic findings are consistent with involvement by CHRONIC MYELOMONOCYTIC LEUKEMIA (CMML). The presence of less than 5% blasts further categorizes this into CMML-o and a white blood cell count less than  $13 \times 10^9/L$  favors the "dysplastic type" according to the 2016 revision to the WHO (Arber DA et al, Blood 2016).

Electronically Signed By: Demetrios Braddock, MD, PhD

**MICROSCOPIC DESCRIPTION:**

Marrow Cellularity: Markedly hypercellular for age (90%)  
Megakaryocytes: Moderately increased, occur in occasional clusters and include occasional small, hypolobated and dysplastic forms.  
Myeloid Maturation: Normal  
Erythroid Maturation: Normal  
Myeloid:Erythroid Ratio: Mildly increased  
Lymphoid Aggregates: Two lymphoid aggregates composed of small sized cells, comprise less than 5% of the marrow cellularity.  
Granulomas: Not seen  
Marrow Trabeculae: Normal  
Hemosiderin: Present  
Iron Stain: Focal stainable iron is present in this decalcified specimen  
Marrow Reticulin: Mildly, diffusely increased  
Clot Preparation: Similar to the core biopsy  
PAS / Giemsa: Evaluated  
Special Stains: Giemsa, Iron, PAS, Reticulin  
Immunostains: CD34 highlights less than 5% of the marrow cellularity. The lymphoid aggregates are predominantly composed of CD20 positive B cells with a few admixed CD3 positive T cells, all of which are negative for cyclin D1. The purpose for these ancillary tests is to evaluate the percentage of immature myeloid forms and the lymphoid aggregates.

**ADDITIONAL STUDIES:**

Stain	Result
CD3 (MRQ-39)	See microscopic description above.
CD20 (L26)	See microscopic description above.
Cyclin D1 (SP4)	See microscopic description above.
CD34 (QBEnd/10)	See microscopic description above.

**GROSS DESCRIPTION:**

1.) The specimen is received in formalin labeled with the patient's initials and requisition number, and consists of 1 piece of bone marrow core measuring 2.0 x 0.2 x 0.2 cm. The specimen is submitted in 1 cassette after decalcification. 2.) The specimen is received in formalin labeled with the patient's initials and requisition number, and consists of 1 piece of marrow clot measuring 2.0 x 1.0 x 0.8 cm. The specimen is submitted in 1 cassette.

Disclaimer: The adequacy of staining is verified by the appropriate positive & negative controls. The reagents used for these assays are analyte specific reagents (ASR). Their performance characteristics have been validated by Precipio Diagnostics, LLC, New Haven, CT. They have not been reviewed by the FDA. The FDA has deemed that such approval is unwarranted. These assays are for clinical use and should not be viewed as experimental or "research use only".



**BONE MARROW ASPIRATE**

**DIAGNOSIS:**

Bone marrow, aspirate: Maturing trilineage hematopoiesis with occasional trilineage dysplasia and a monocytosis

Electronically Signed By: Demetrios Braddock, MD, PhD

**SMEAR REVIEW:**

The marrow aspirate smear is spicular and cellular for diagnostic evaluation. Megakaryocytes are moderately increased in number with occasional atypical forms. The myeloid : erythroid (M:E) ratio is approximately 4:1. Erythroid elements exhibit maturation and include occasional dysplastic forms with irregular nuclear contours. Myeloid elements exhibit maturation and include occasional dysplastic forms with decreased granularity. No increase in eosinophilic forms is seen. No increase in immature cells is noted. Iron, but no increase in ring sideroblasts is detected on iron stain of the marrow aspirate.

Number of cells counted: 501

Cell Type	Percent	Ref. Range
Blasts	1%	0.3 - 3.0 %
Immature Myeloid	14%	12.0 - 21.0 %
Mature Myeloid	57%	35.0 - 55.0 %
Eosinophils	1%	1.0 - 3.0 %
Basophils	0%	0.0 - 1.0 %
Lymphocytes	2%	10.0 - 15.0 %
Plasma Cells	0%	0.0 - 1.0 %
Monocytes	6%	0.0 - 1.0 %
Erythroid	18%	15.0 - 25.0 %
M:E ratio	4:1	2 - 4:1



**DIAGNOSIS:**

Bone marrow, aspirate: Monoclonal B-cell lymphocytosis (MBL) (see comment)

**COMMENT:**

In the setting of an absolute lymphocyte count of  $2.8 \times 10^9/L$ , the presence of a CD5 positive, clonal population of B cells is consistent with a Monoclonal B-Cell Lymphocytosis (MBL). According to the 2016 WHO classification this falls into a "high count" MBL (between  $0.5$  and  $5.0 \times 10^9/L$ ), for which routine annual follow-up is advised (Swerdlow SH et al., Blood 2016). In addition, less than 5% CD34 positive blasts are identified, supporting the blast count by aspirate smear.

Electronically Signed By: Demetrios Braddock, MD, PhD

**INTERPRETATION:**

The differential shows increased granulocytes (88%). There is a total of 2% CD34 positive cells identified. The lymphocytes (2%) include 29% kappa-restricted B-cells, 60% mature T-cells with a normal CD4/CD8 ratio, and 13% natural killer (NK) cells. The CD138 positive plasma cells (<1%) have a polyclonal kappa/lambda phenotype.

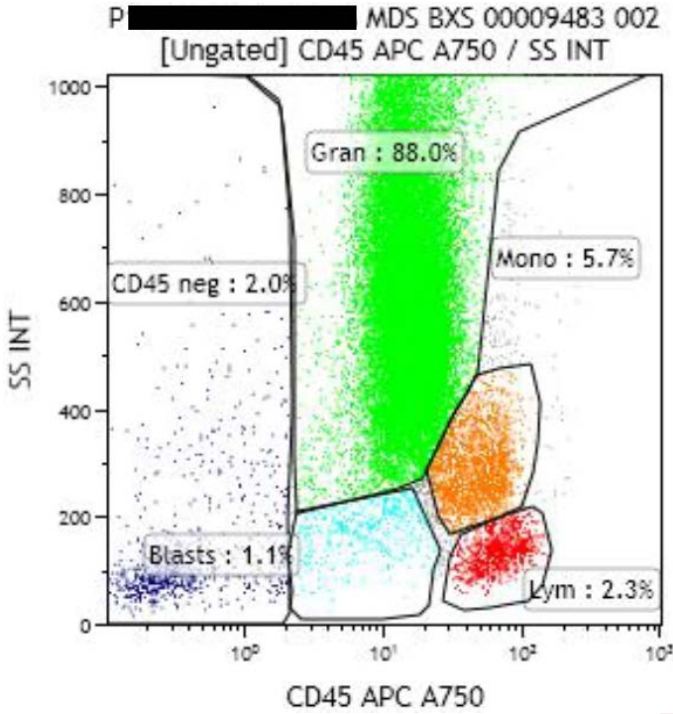
The B-cells show a loss of surface light chain expression and are partially positive for CD5, FMC7, and CD23, but negative for CD10 and CD103.

**RESULT:**

**Analysis Time:** 06/10/2011, 10:34 hr

**Viability:** 98% (Normal > 80%)

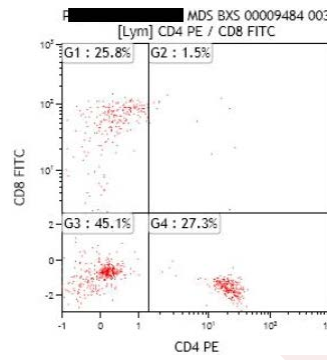
**Specimen:** BM, Lavender-top tube



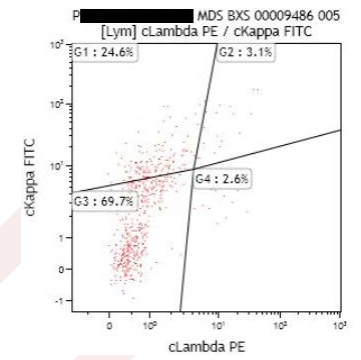
Flow Differential

Flow Cytometry Differential

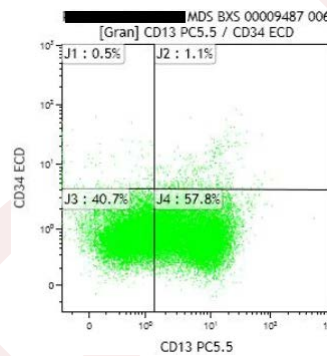
Lymphocytes:	2%
Monocytes:	6%
Granulocytes:	88%
Plasma Cells:	<1%
Blasts:	1%
nRBC & Debris:	2%



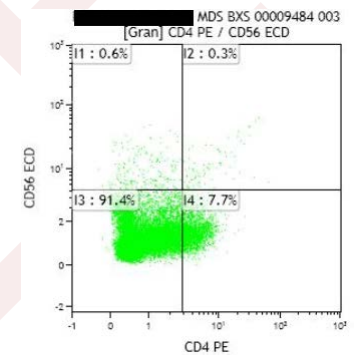
Normal CD4/CD8 Ratio



Kappa Restricted B-Lymphocytes



CD13+ Granulocytes



CD56- Granulocytes

**Granulocytes Gated Population (CD45 and side scatter)**

T/NK-cell	%	Myelo/Mono	%	Precursor	%	B-Cell	%
CD4	8	HLA-DR	5	CD34	2	CD10	28
CD56	1	CD13	59	CD117	9	CD19	2
		CD11b	83				
		CD16	48				
		CD64	61				
		CD15	5				
		CD71	1				
		CD14	17				
		CD61	21				
		CD33	98				
<b>Other</b>	<b>%</b>						
CD45	100						

**Lymphocytes and Plasma Gated Population (CD45 and side scatter)**

T/NK-cell	%	B-Cell	%	Other	%
CD8	26	Kappa	25	CD45	100
CD4	27	Lambda	3		
CD56	13	CD20	28		
CD2	73	CD38	11		
CD3	60	CD10	<1		
CD5	68	CD19	28		
CD7	73	sKappa	8		
		sLambda	5		
		FMC-7	13		
		CD79b	17		
		CD23	7		
		CD25	14		
		CD11c	4		
		CD103	1		
		ZAP-70	1		

Intensity: B = bright D = dim M = moderate

Disclaimer: The adequacy of staining is verified by the appropriate positive & negative controls. The reagents used for these assays are analyte specific reagents (ASR). Their performance characteristics have been validated by Precipio Diagnostics, LLC, New Haven, CT. They have not been reviewed by the FDA. The FDA has deemed that such approval is unwarranted. These assays are for clinical use and should not be viewed as experimental or "research use only".



**DIAGNOSIS:**

Bone marrow, aspirate: Normal male karyotype (see interpretation)

Electronically Signed By: Demetrios Braddock, MD, PhD  
Department of Cyto genetics  
Precipio Diagnostics

Demetrios Braddock, MD, PhD

**INDICATION:**

Monocytosis, Leukocytosis & Splenomegaly

**KARYOTYPE "ISCN":**

46,XY[20]; Normal Male Karyotype

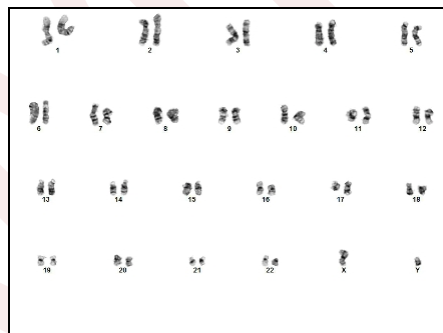
**INTERPRETATION:**

Conventional cytogenetic analysis shows a male karyotype with no evidence of an acquired clonal abnormality. This does not exclude the possibility of an abnormality that cannot be detected at the chromosomal level or exists at a low residual level.


Interpretation of this specimen's cytogenetic results should be made in conjunction with morphologic, immunophenotypic, and clinical findings. The results of this analysis do not exclude the possibility of genetic alterations below the band-resolution of this test or abnormalities due to other etiologies.

**RESULT:**

Analysis	
Cells Counted:	20
Cells Analyzed:	20
Cells Imaged:	3
Cells Karyotyped:	3
Banding Type:	G-Banding
Band Level:	450



Normal Karyotype



Normal Karyotype



**DIAGNOSIS:**

Bone marrow, aspirate: No Clonal Abnormalities Detected, see interpretation below.

Electronically Signed By: Demetrios Braddock, MD, PhD

**FISH "ISCN":**

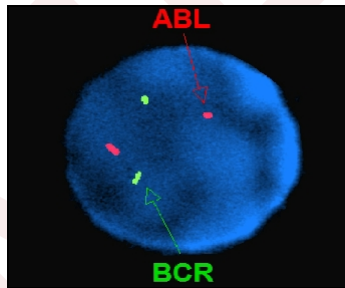
nuc ish (ABL,BCR)x2[200]

**INTERPRETATION:**

Fluorescence in situ hybridization (FISH) with a panel of probes specific for detection of recurring chromosome abnormalities in CML was performed on uncultured bone marrow cells.

The regions/loci represented in these probe mixes were:

BCR/ABL, dual color, dual fusion translocation probes, specific for detection of BCR /ABL fusion [t(9;22)], reveal a hybridization pattern within normal limits in 200 analyzed nuclei.



No ABL/BCR Translocation

Disclaimer: The adequacy of staining is verified by the appropriate LSI controls. The reagents used for these assays are analyte specific reagents (ASR). Their performance characteristics have been validated by Precipio Diagnostics, LLC, New Haven, CT. They have not been reviewed by the FDA. The FDA has deemed that such approval is unwarranted. These assays are for clinical use and should not be viewed as experimental or "research use only".